

Liver tumors

Pr : Mohsen BILAL

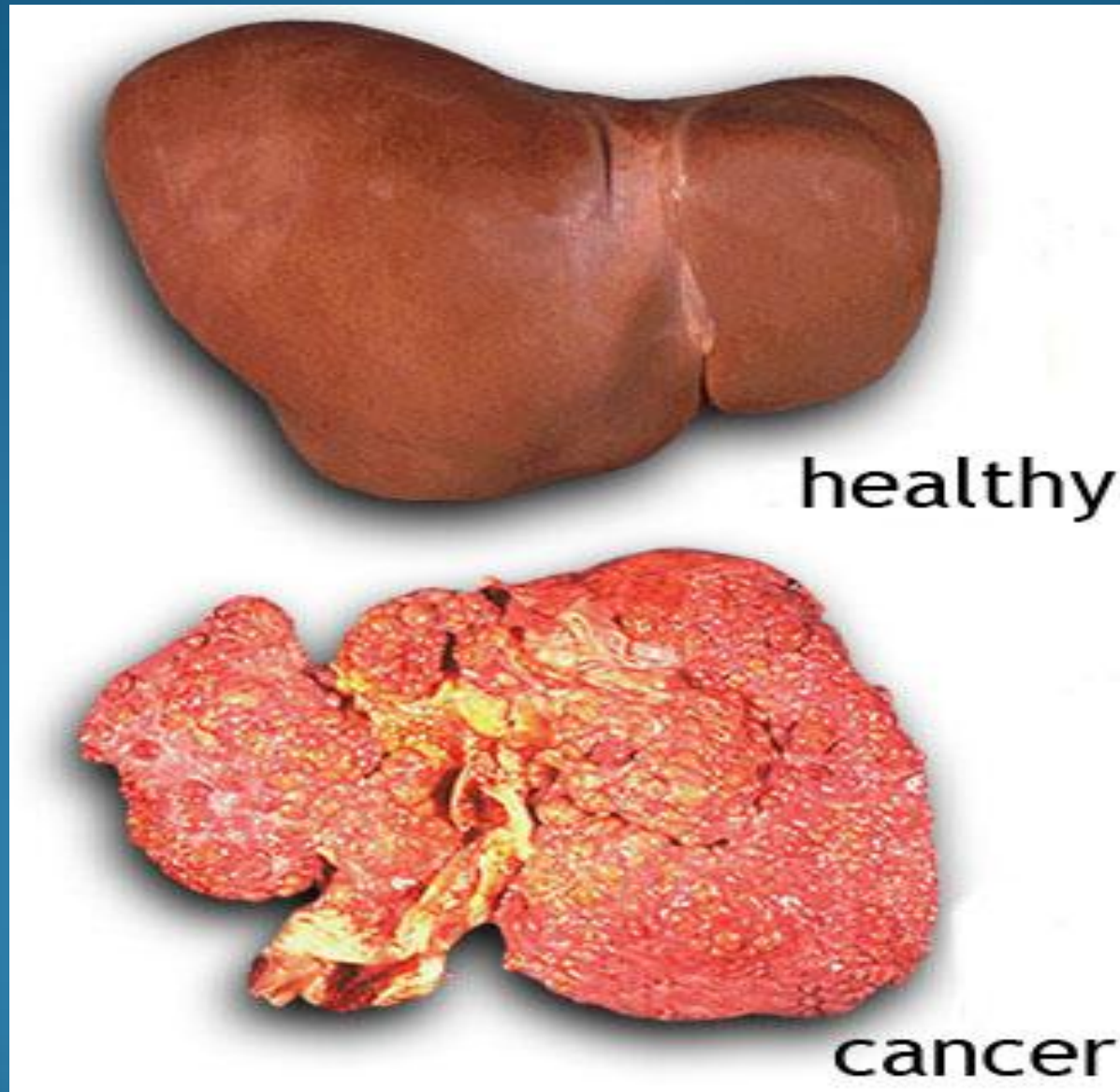
Liver tumors

Tumors can either be benign or malignant .

benign tumors grow uncontrolled , then do not break off and spread beyond where they started and not invade into the surrounding tissues .

malignant tumors , will invade and damage other tissues around them . they can also gain the ability to break off from where they started and spread to other parts of the body (metastasize) , usually through the blood stream or through the lymphatic system where the lymph nodes are located.

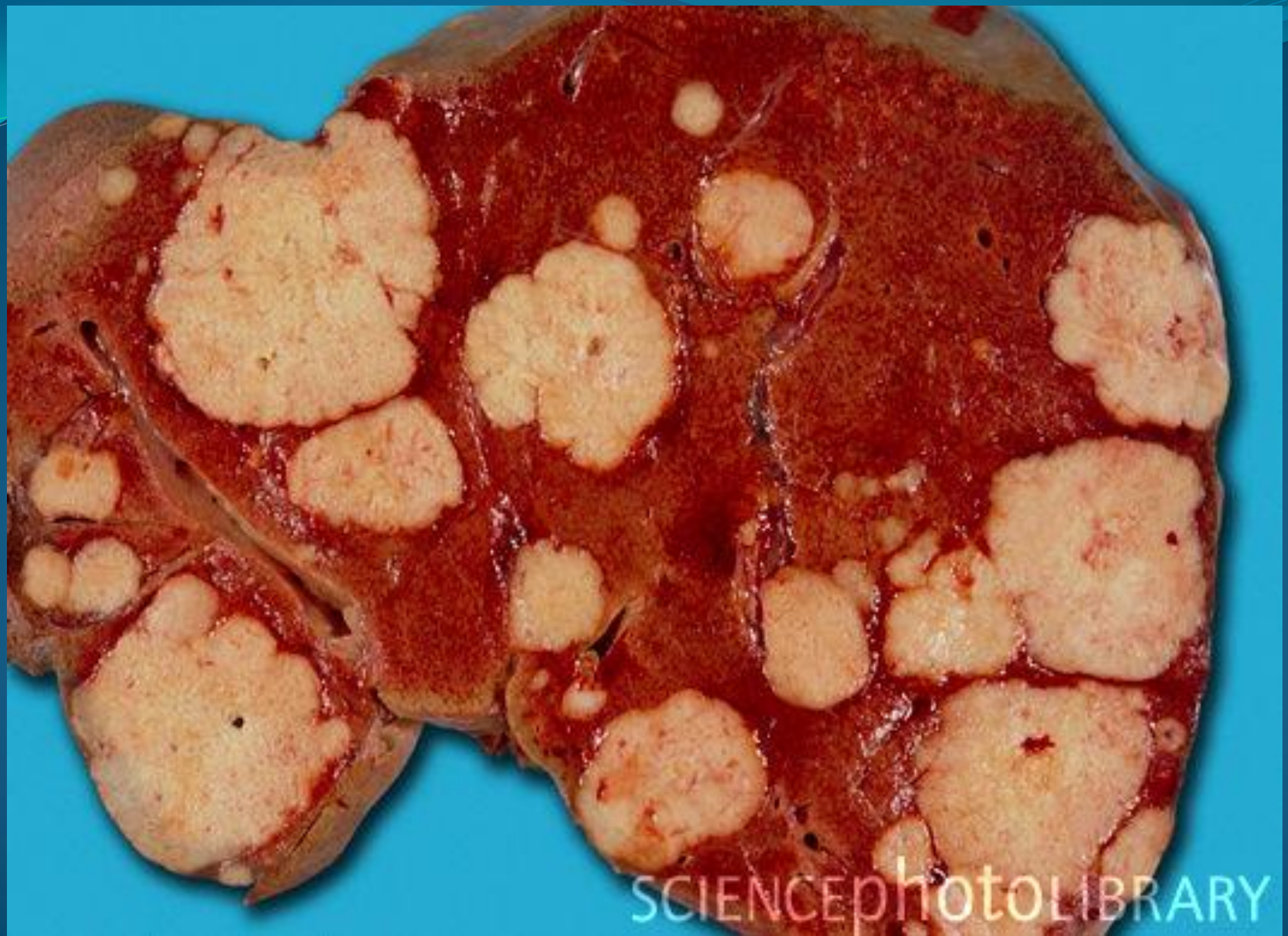Liver tumors



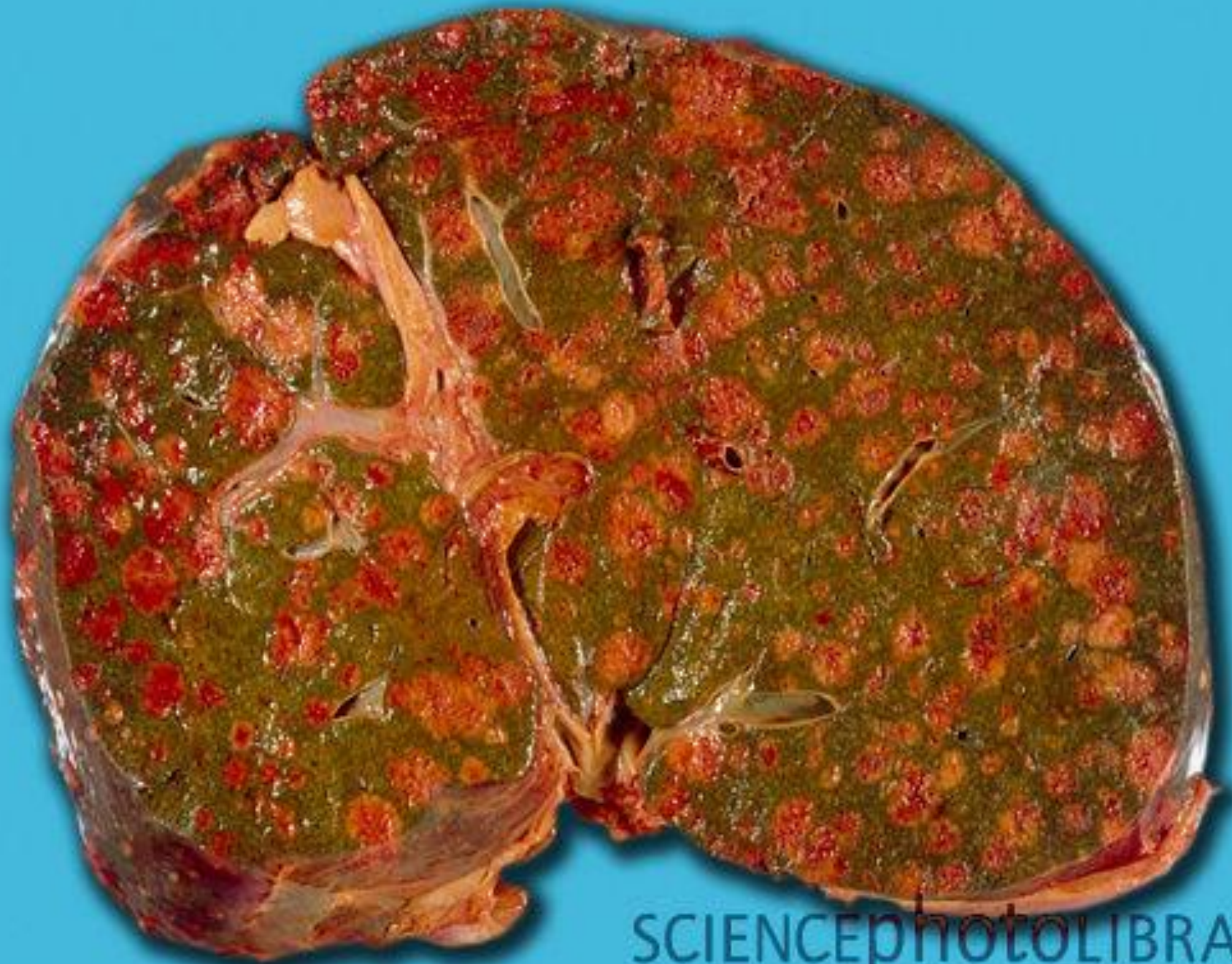
Liver tumors

over time , the cells of a malignant tumor become more abnormal and appear less like normal cells . this change in the appearance of cancer cells is called the tumor grade , and cancer cells are described as being **well – differentiated , moderately – differentiated , poorly – differentiated , or undifferentiated**

well – differentiated cells are quite normal appearing and resemble the normal cells from which they originated . undifferentiated cells are cells that have become so abnormal that , we cannot tell what types of cells they started from .

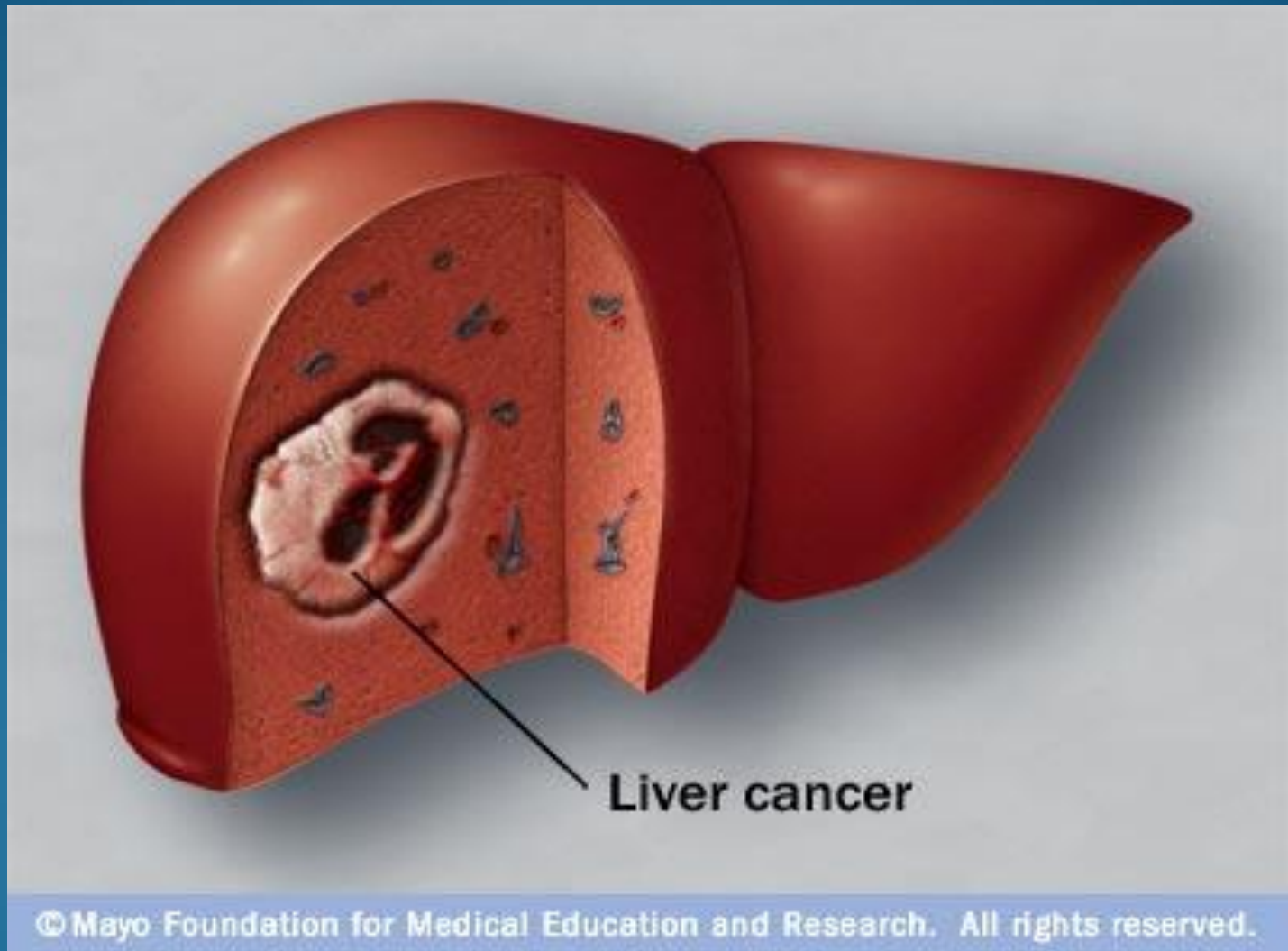


SCIENCEphOTO LIBRARY



SCIENCEPHOTOLIBRARY

Liver cancer



Liver tumors

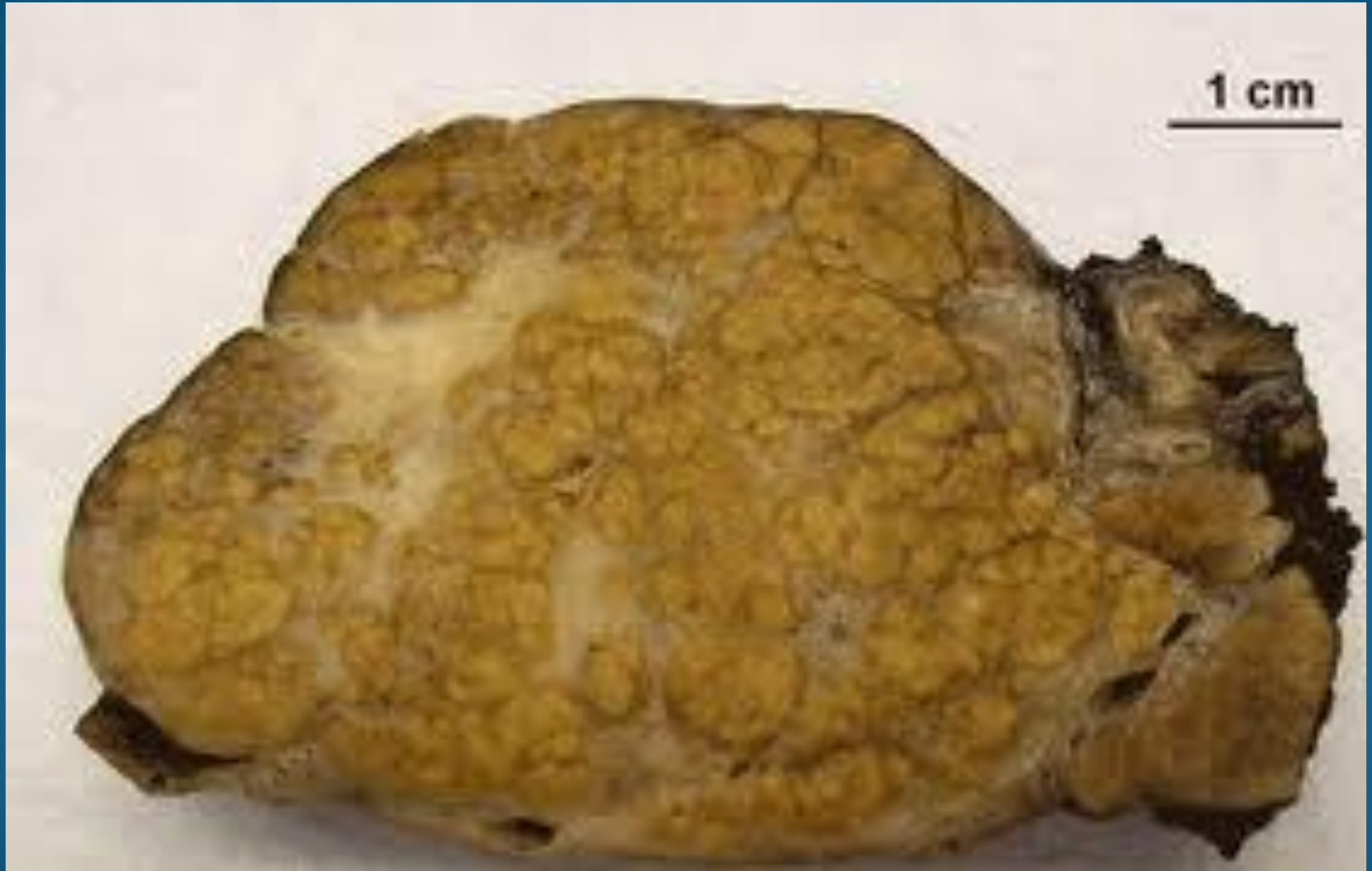There are a number of benign liver tumors :

adenomas

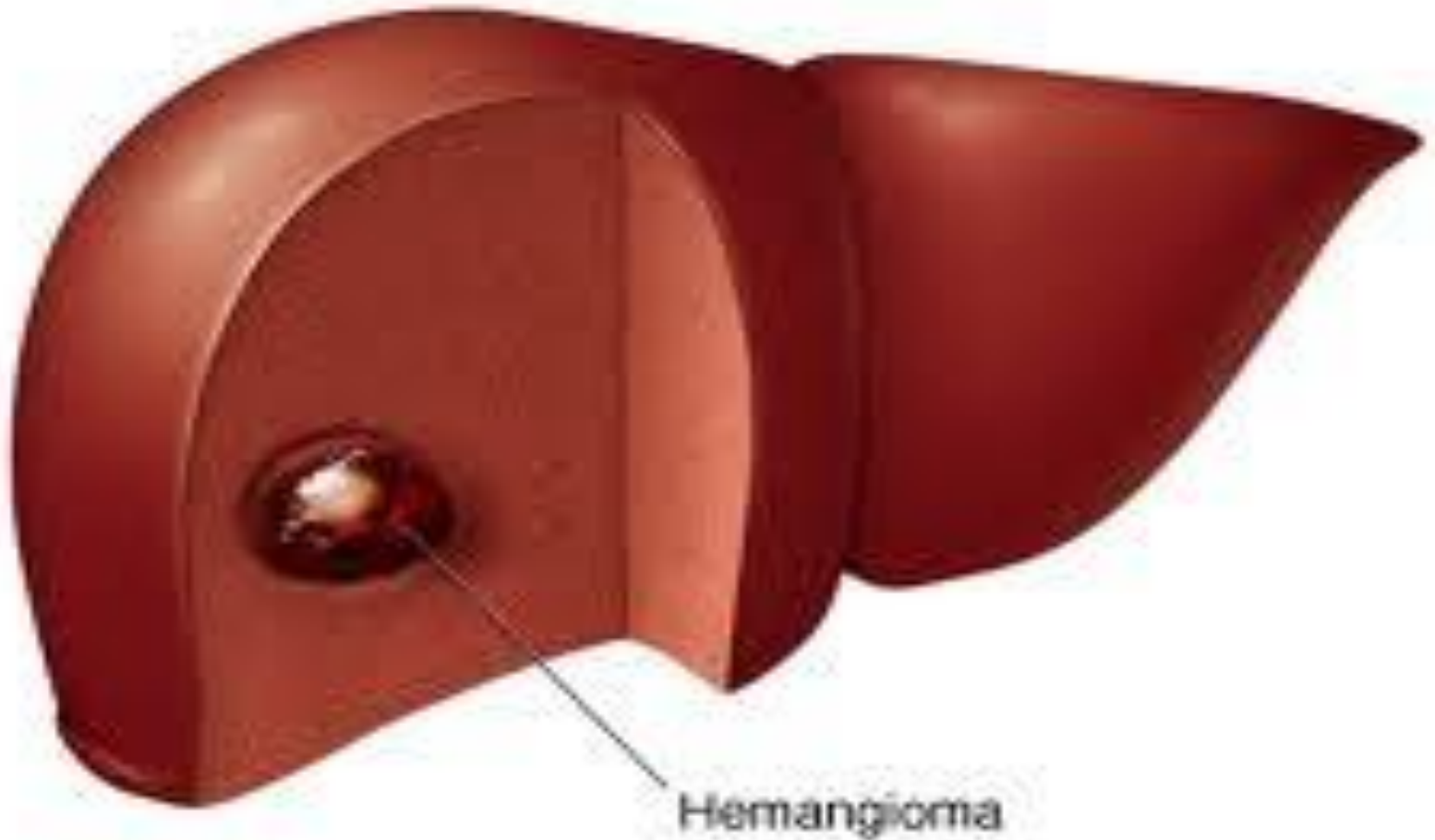
Hemangiomas

primary liver cancers can arise from within the liver is the most itself . **hepatocellular carcinoma (HCC)** , is the most common type of primary liver cancer and accounts for around 70% of all liver cancers

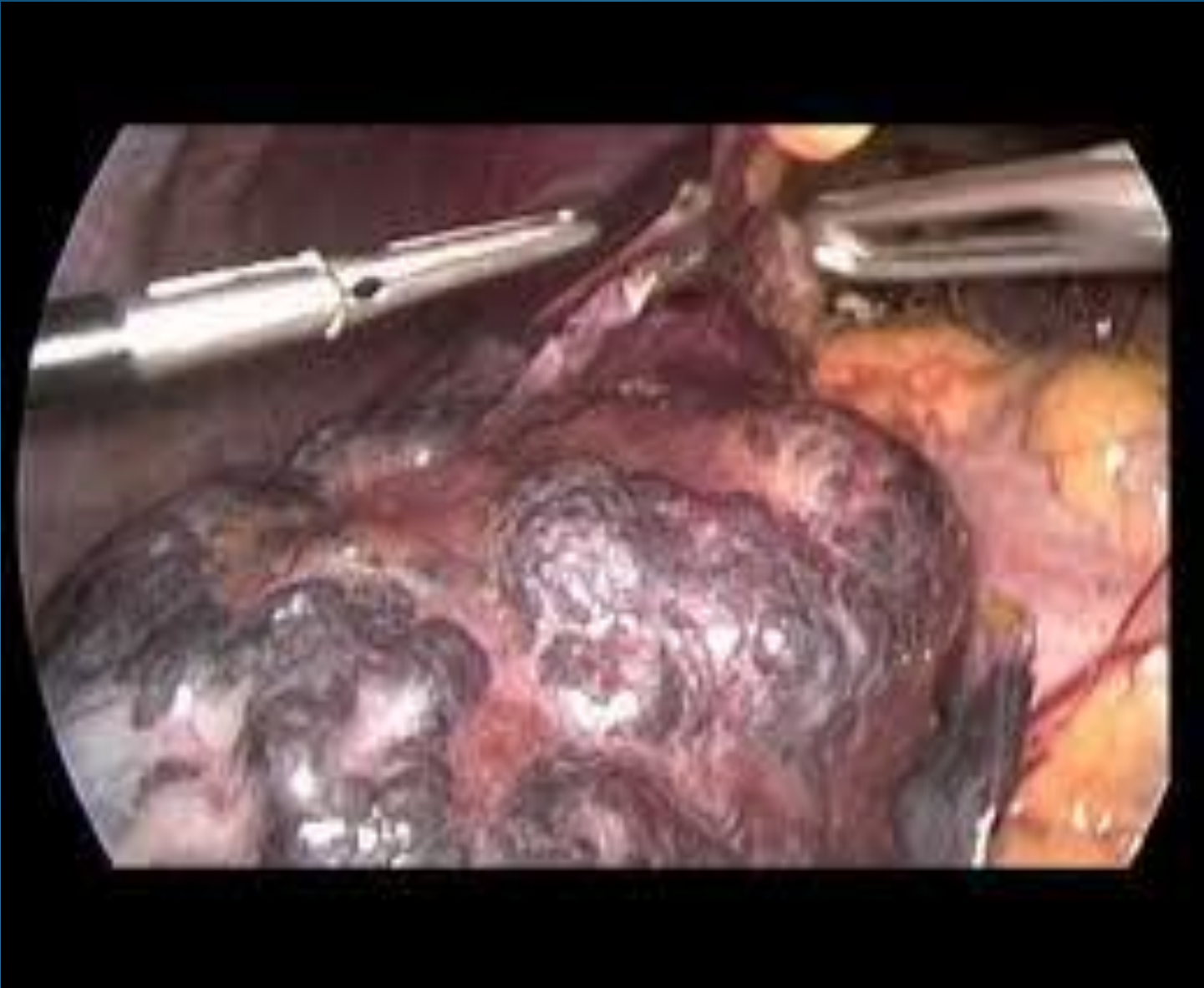Liver tumors



Hemangioma



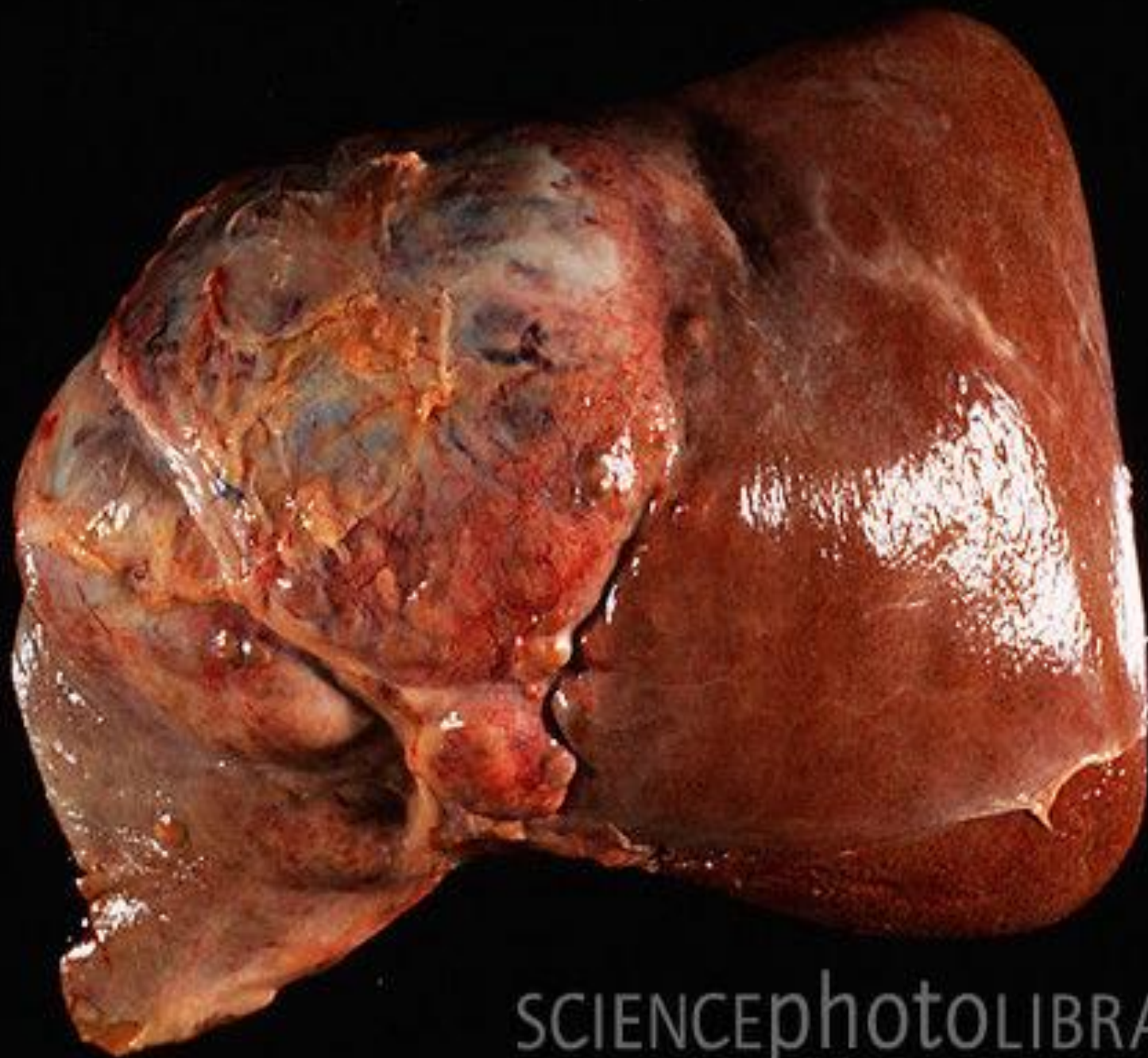
Hemangioma



Liver tumors

cancers that arise from the bile ducts within the liver are known as cholangiocarcinomas and represent 10 – 20% of all liver cancers .

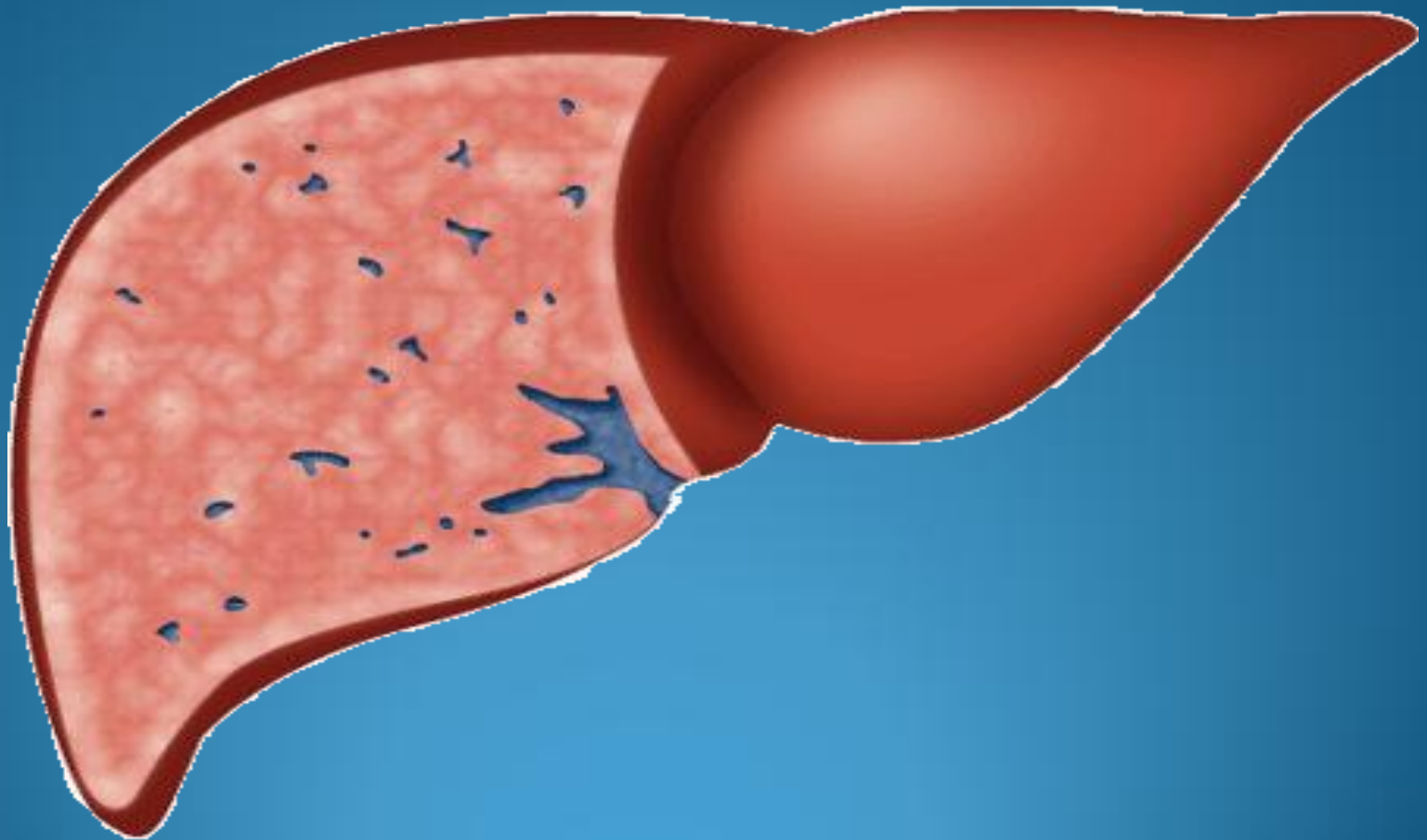
other types of rare cancers can occur within the liver . these include **hemangiosarcomas** (malignant blood – filled tumors) and **hepatoblastoma** (a rare cancer that develops in very young children) ..



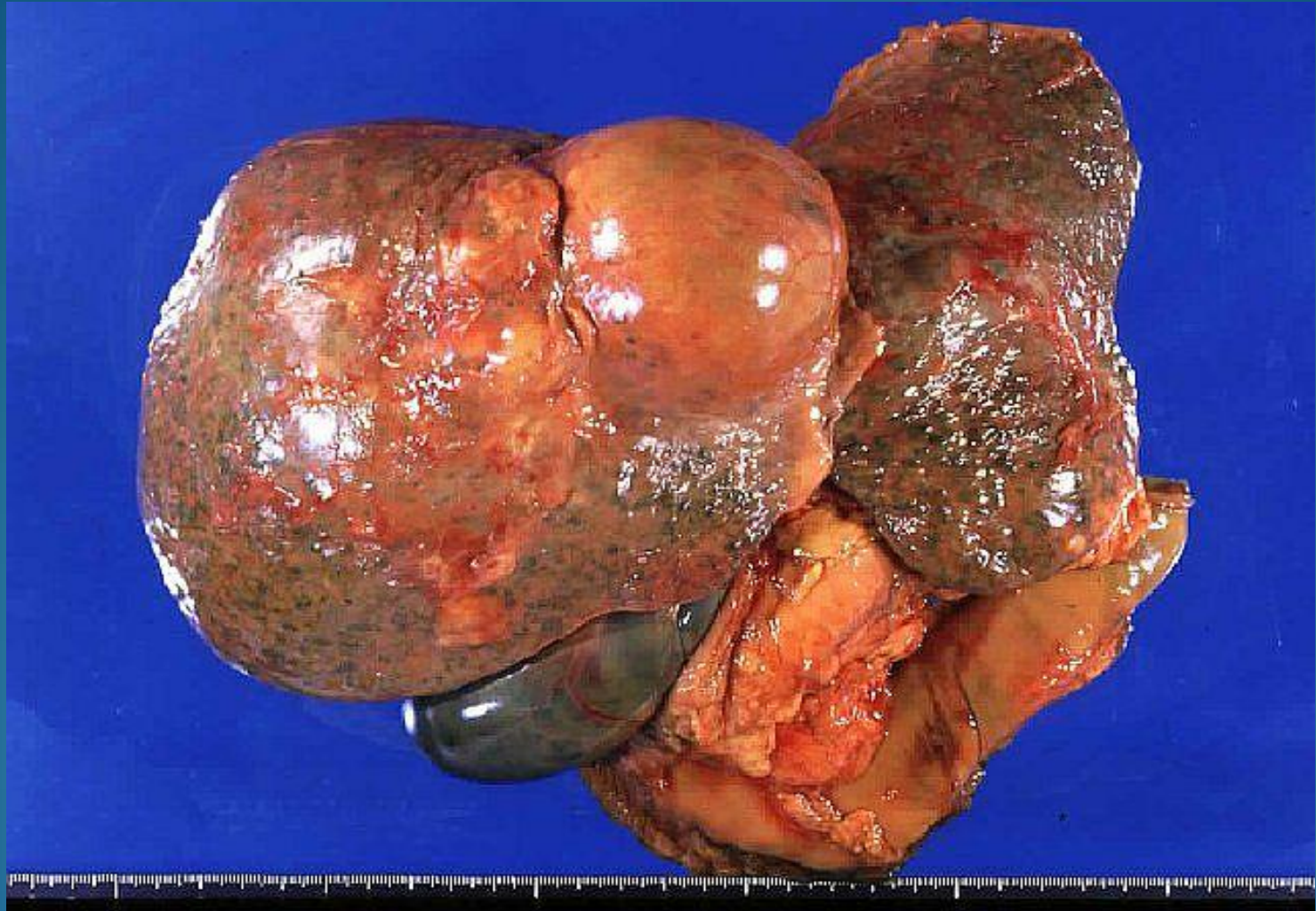
SCIENCEphOTO LIBRARY

HCC

Hepatocellular carcinoma tumor spreads
until it reaches the surface of the liver



HCC



Risk factors

Cirrhosis :

chronic alcohol

chronic infection with hepatitis B , C virus (HBV, HCV)

Tobacco

aflatoxin B food contamination .

environment factors include exposure to thorium dioxide (thorotrast , a contrast agent previously used for radiographic imaging . .

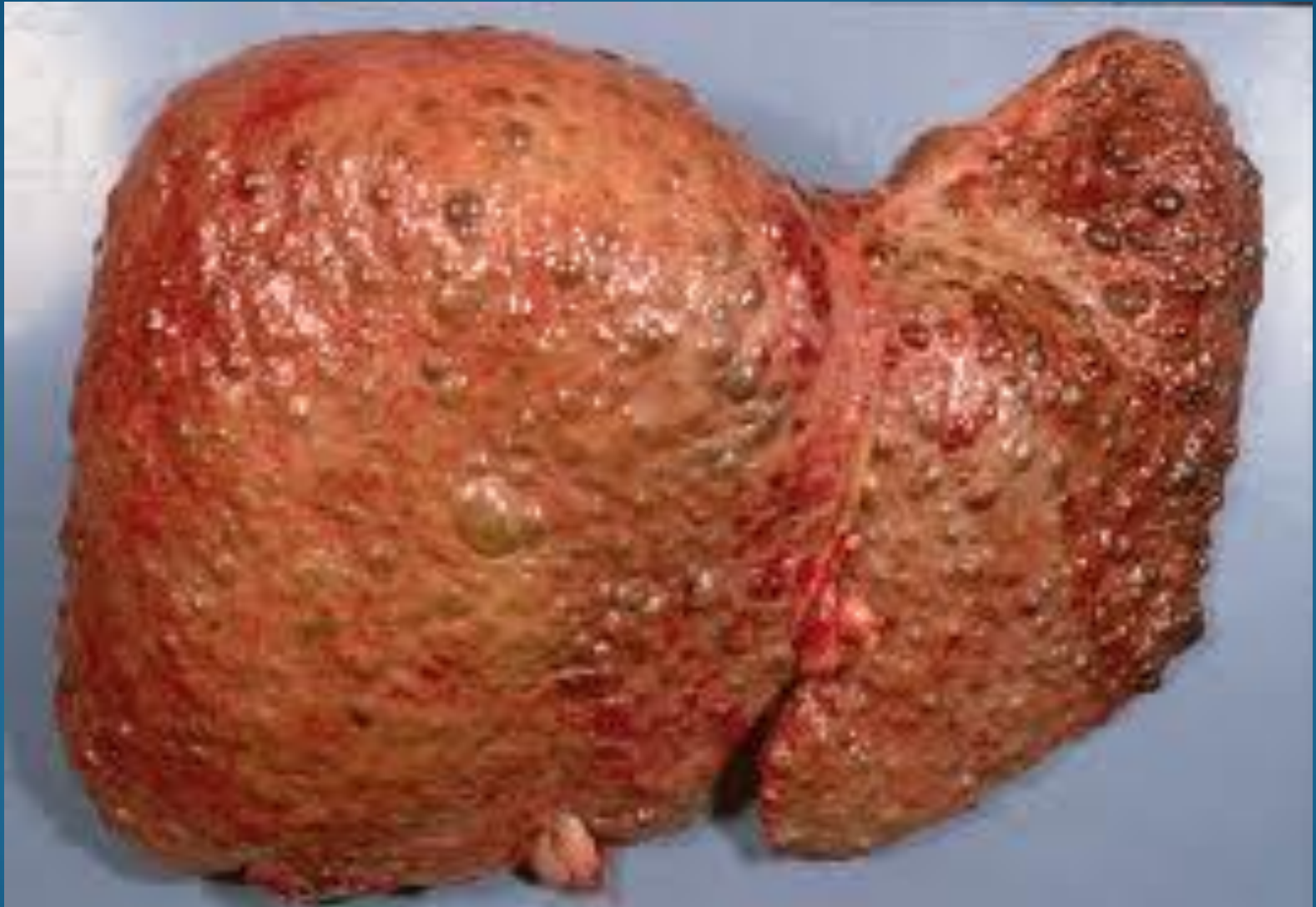family history

hemochromatosis .

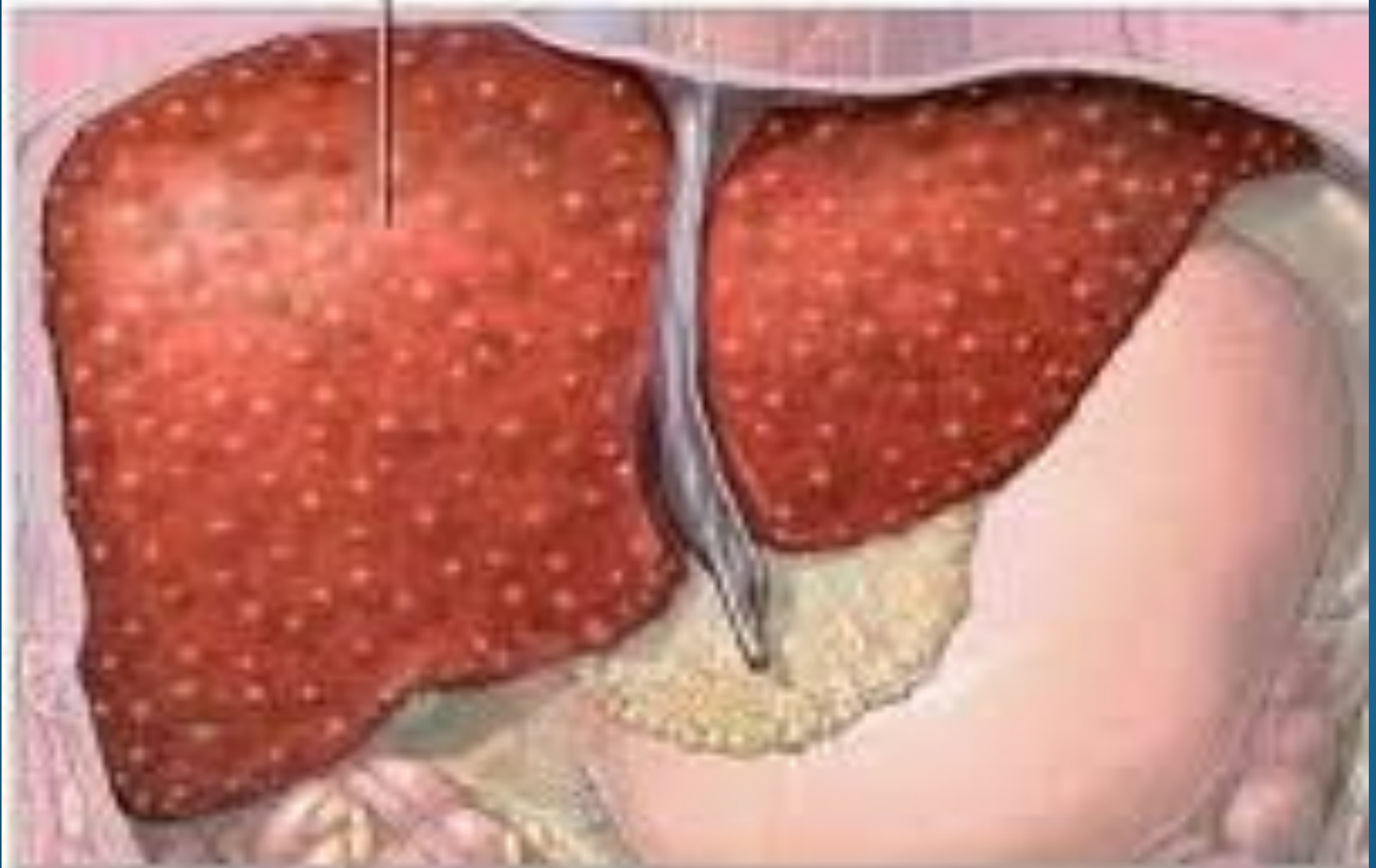cirrhosis



cirrhosis



Cirrhosis of the liver



How to prevent liver cancer ?

avoiding the excessive use of alcohol and quitting smoking can reduce the risk of liver cancer .

treating HBV and HCV infections .

altering the way that foods are stored and processed can decrease the risk of aflatoxin exposure .

treatment of inherited diseases associated with cirrhosis and liver cancer .

Signs & symptoms

abdominal pain , feeling of abdominal fullness or bloating (sometimes due to ascites , or a collection of fluid within the abdominal cavity) , fatigue , loss of appetite , and weight loss .

liver cancer generally does not have symptoms .

nonspecific symptoms that can be associated with HCC may include :

yellowish color of the skin (jaundice)

inability to eat (anorexia)

weight loss

abdominal pain and /or swelling

Diagnosis

Ultrasound echo -

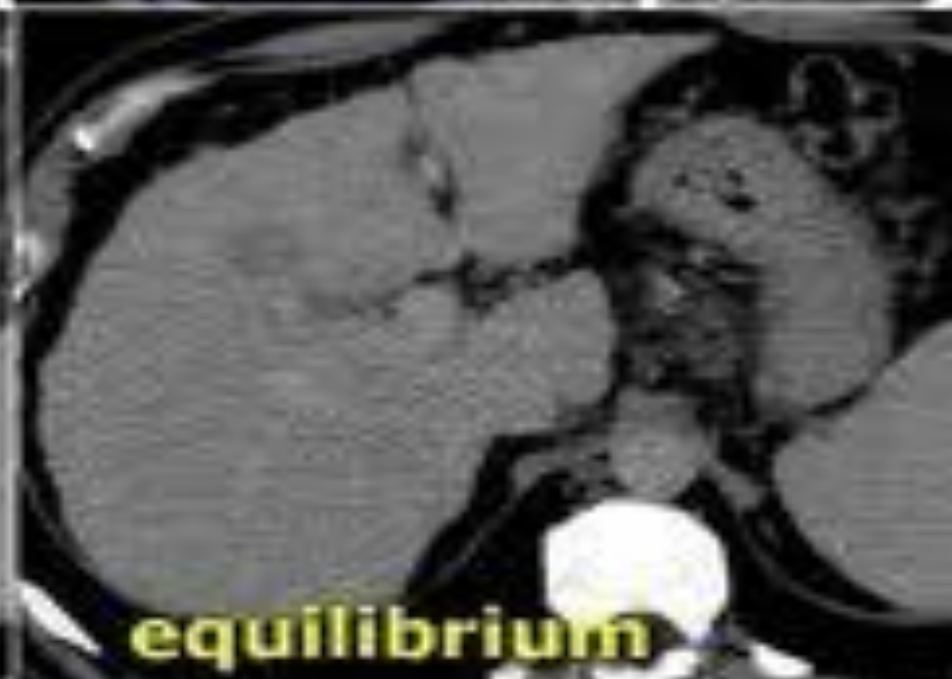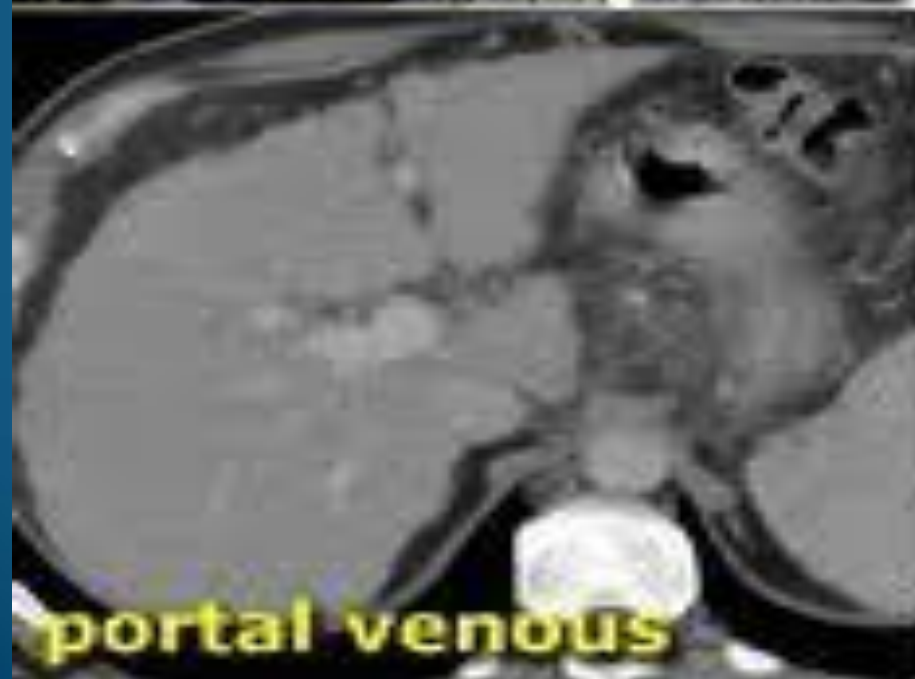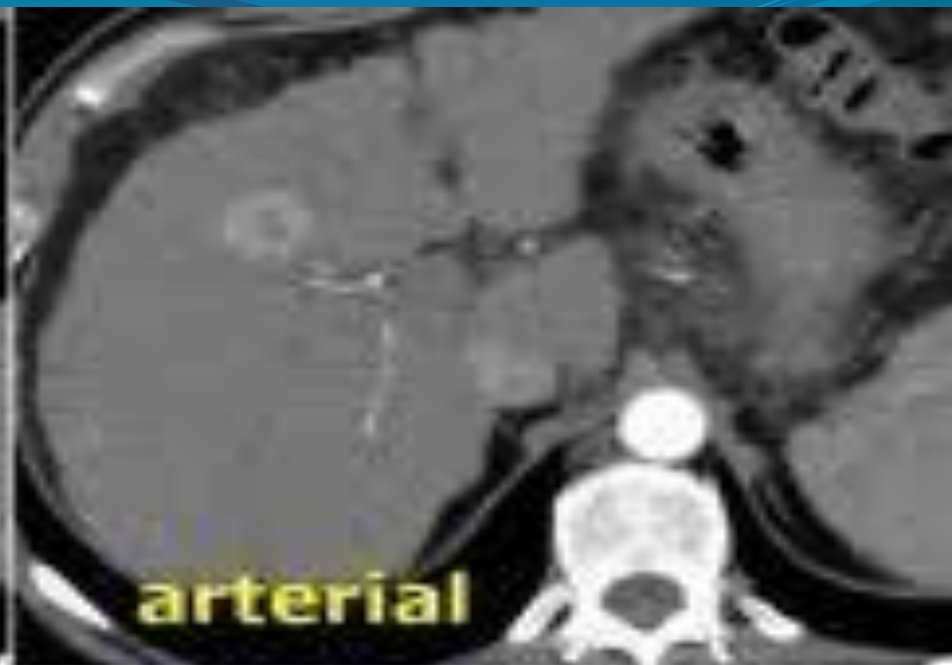
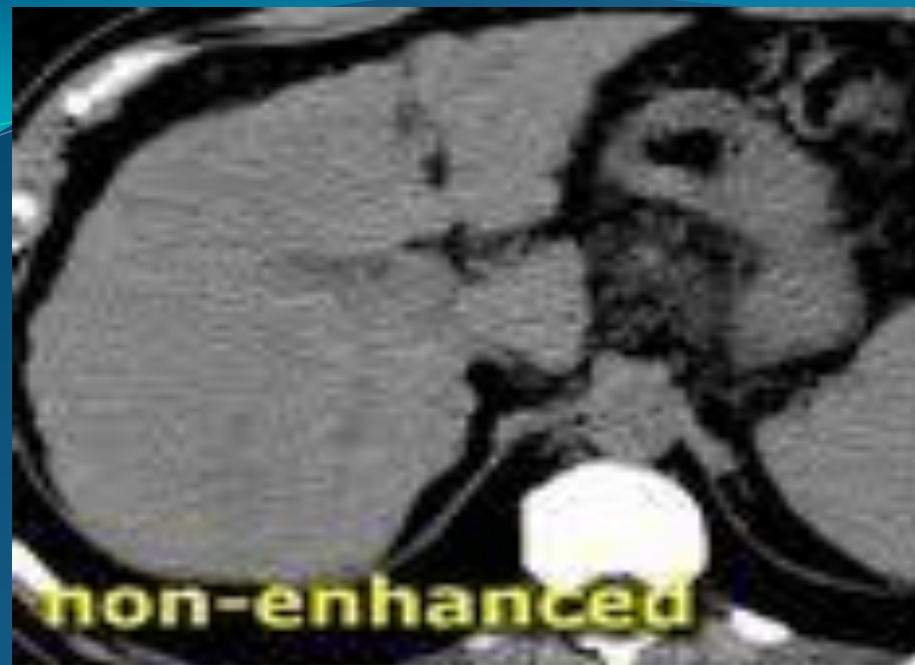MRI -

computed tomography CT

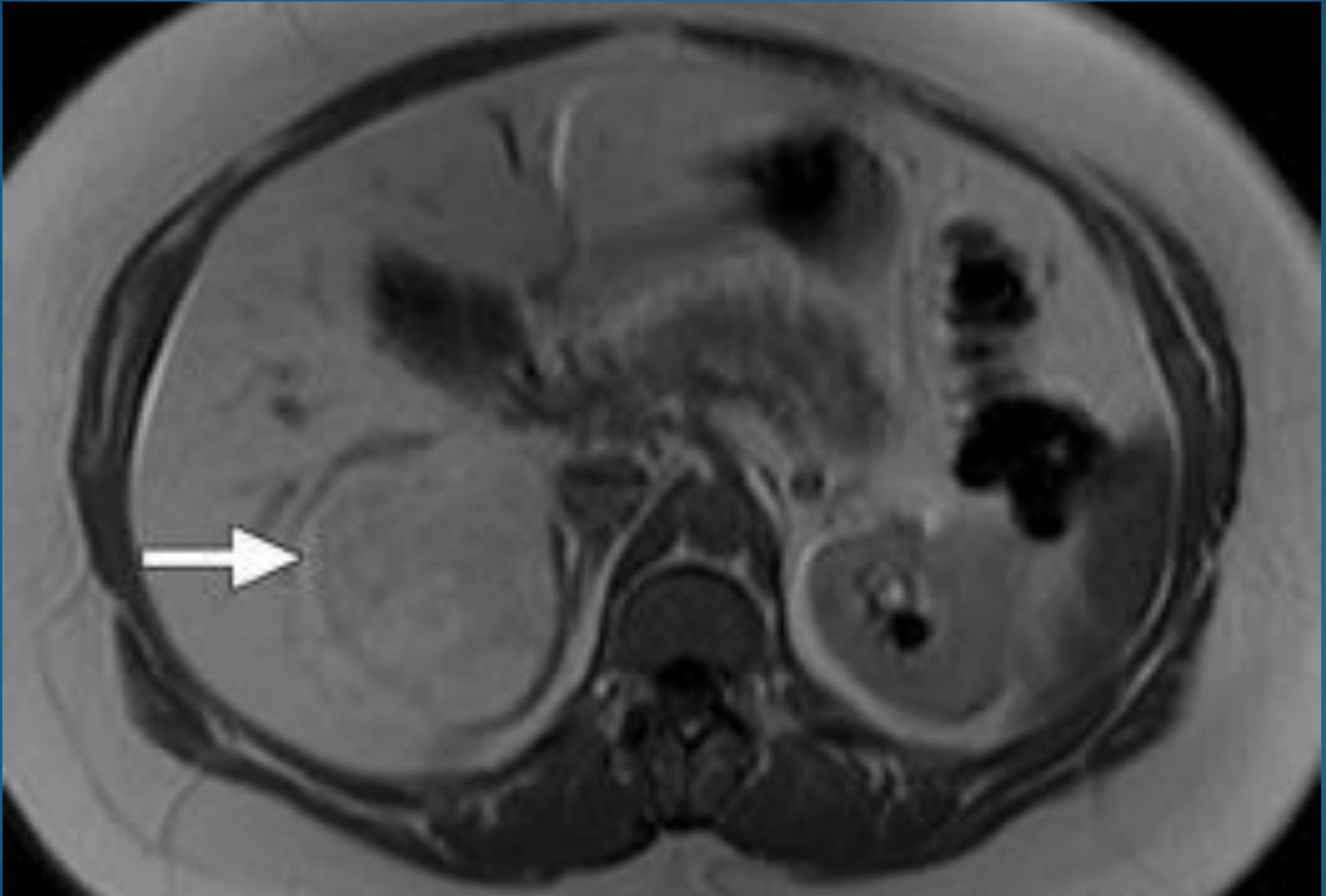
Angiography

elevated AFP

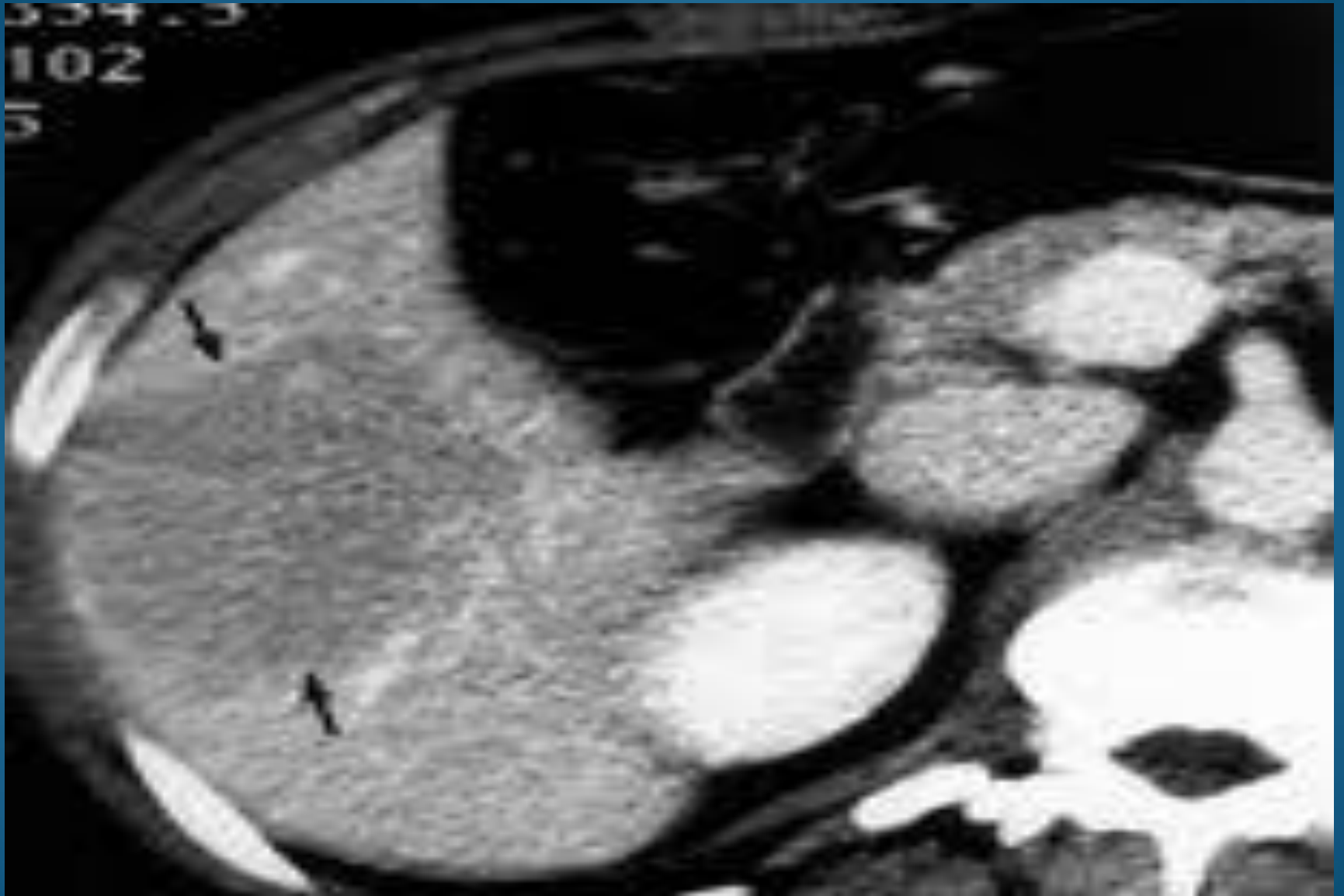
Biopsy



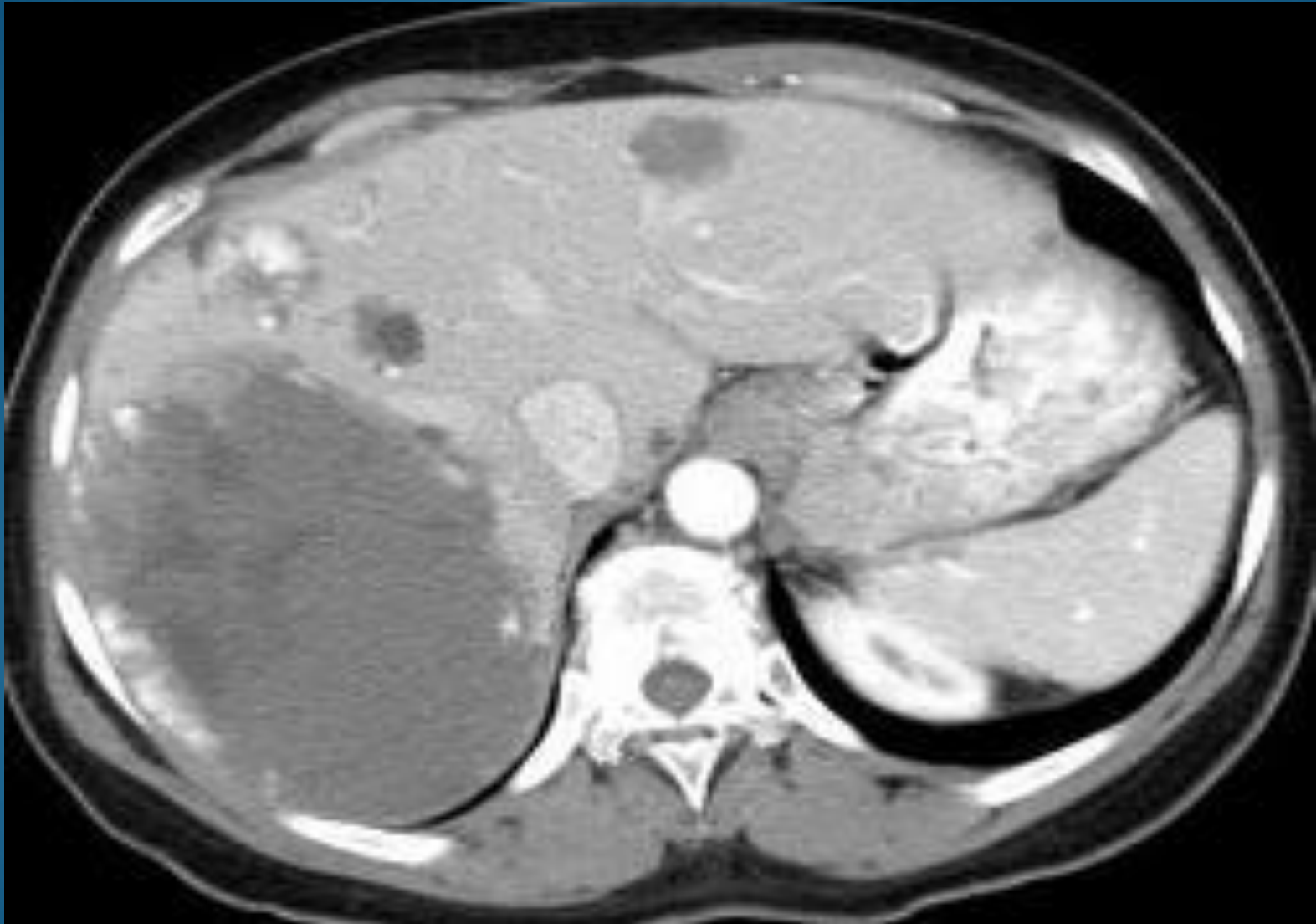adenocarcinoma



adenocarcinoma



hemangioma



Liver cancer stages

T stages :

TX : primary tumor cannot be assessed .

T0 : no evidence of primary tumor .

T1 : solitary tumor without invasion of blood vessels in the liver (not including major branches of the portal of hepatic vein) .

T2 : solitary tumor with invasion of blood vessels in the liver (not including major branches of the portal of hepatic vein) or multiple tumors , non of which are > 5 cm in size .

T3a : multiple tumors at least one of which is > 5 cm in size .

T3b : single tumor or multiple tumors of any size that involves a major branch of the portal vein or hepatic vein .

T4 : tumors that directly invade into adjacent organs (not including the gall bladder) or a tumor that invades the lining of the abdomen .

Liver cancer stages

N stage :

NX: the regional lymph nodes cannot be assessed .

N0 : no evidence of spread to the lymph node .

N1 : regional lymph nodes are involved with tumor .

Liver cancer stages

M stage :

Mo : no evidence of distant spread of the cancer .

M1 : evidence of distant spread of the cancer including spread to non – regional lymph node chain .

Diagnosis of Gallbladder and Bile Duct Cancers

RADIOLOGY TESTS:

MRI

ERCP

Computed Tomography (CT) Scanning

Ultrasound echo

PATHOLOGY TESTS: FNA , biopsy

SEROLOGY TESTS: **CA19-9**

Liver cancer stages

Stage I : T1 N0 M0

Stage II : T2 N0 M0

Stage IIIA : T3a N0 M0

Stage IIIB : T3b N0 M0

Stage IIIC : any T N0 M0

Stage Iva : (any T N) M0

Stage IVb : any T any N M1

Liver cancer treatment

Surgery

Cryosurgery

Radiofrequency ablation (RFA)

Ethanol injection

Chemotherapy

Transarterial chemoembolization (TACE)

Radiation therapy

Gallbladder cancer

Symptoms of Gallbladder and Bile Duct Cancer

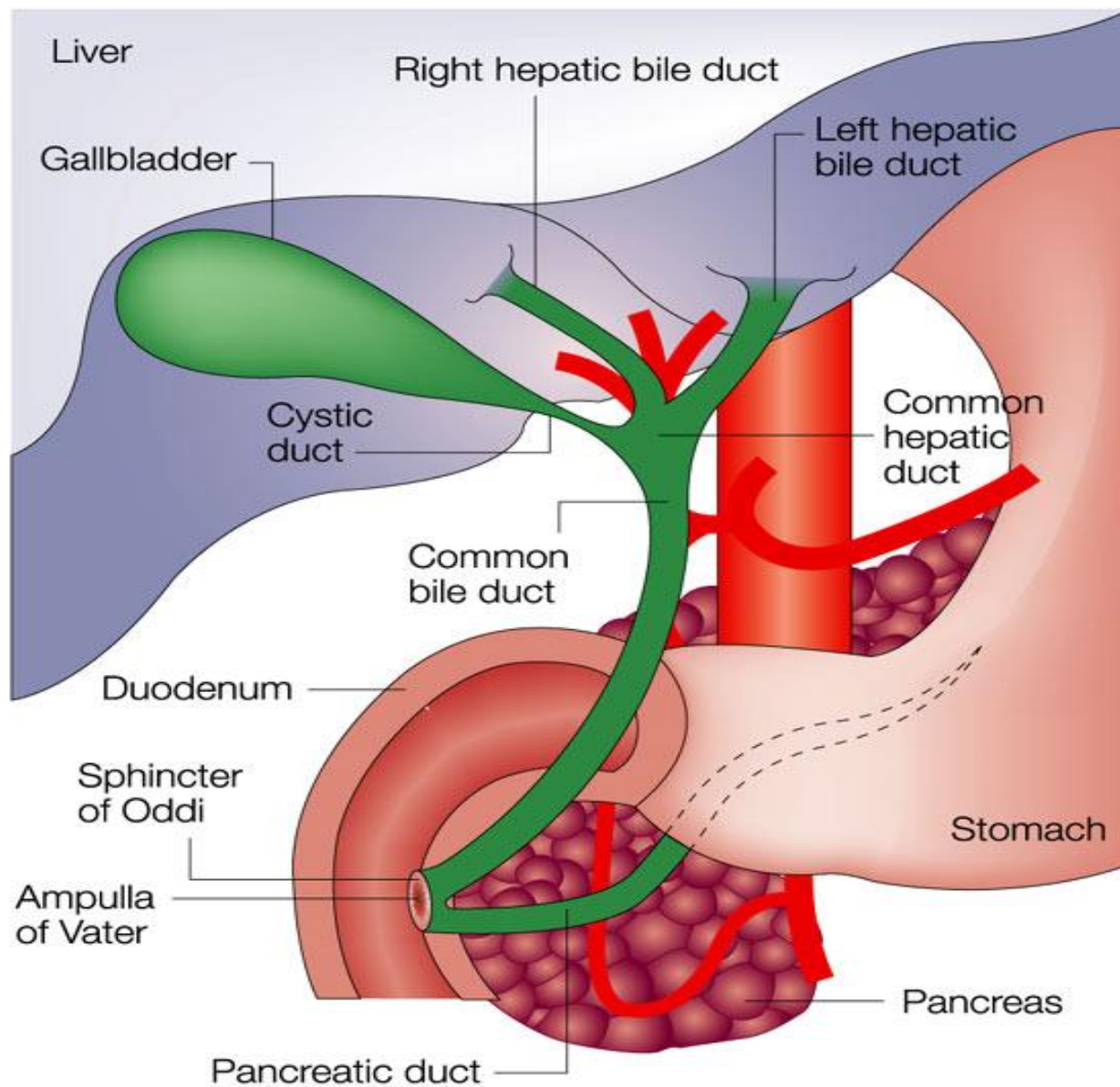
Obstruction of bile ducts :

jaundice (yellowing of the skin and the whites of the eyes) in 90% of patients.

The **jaundice** is usually associated with itching of skin (also called pruritus).

Dark urine (cola colored) , stools become white (clay colored).

pain in the right upper portion of the abdomen.



Gallbladder cancer



Types of Cancers

adenocarcinomas

cholangiocarcinoma

papillary tumors.

rhabdomyosarcoma

carcinomas

Other risk factors for gallbladder cancer

Calcification of the gallbladder wall

Benign polyps

Chronic bacterial infections of the biliary tract

Other risk factors for gallbladder cancer

Carcinoma of the extrahepatic and intrahepatic bile ducts:

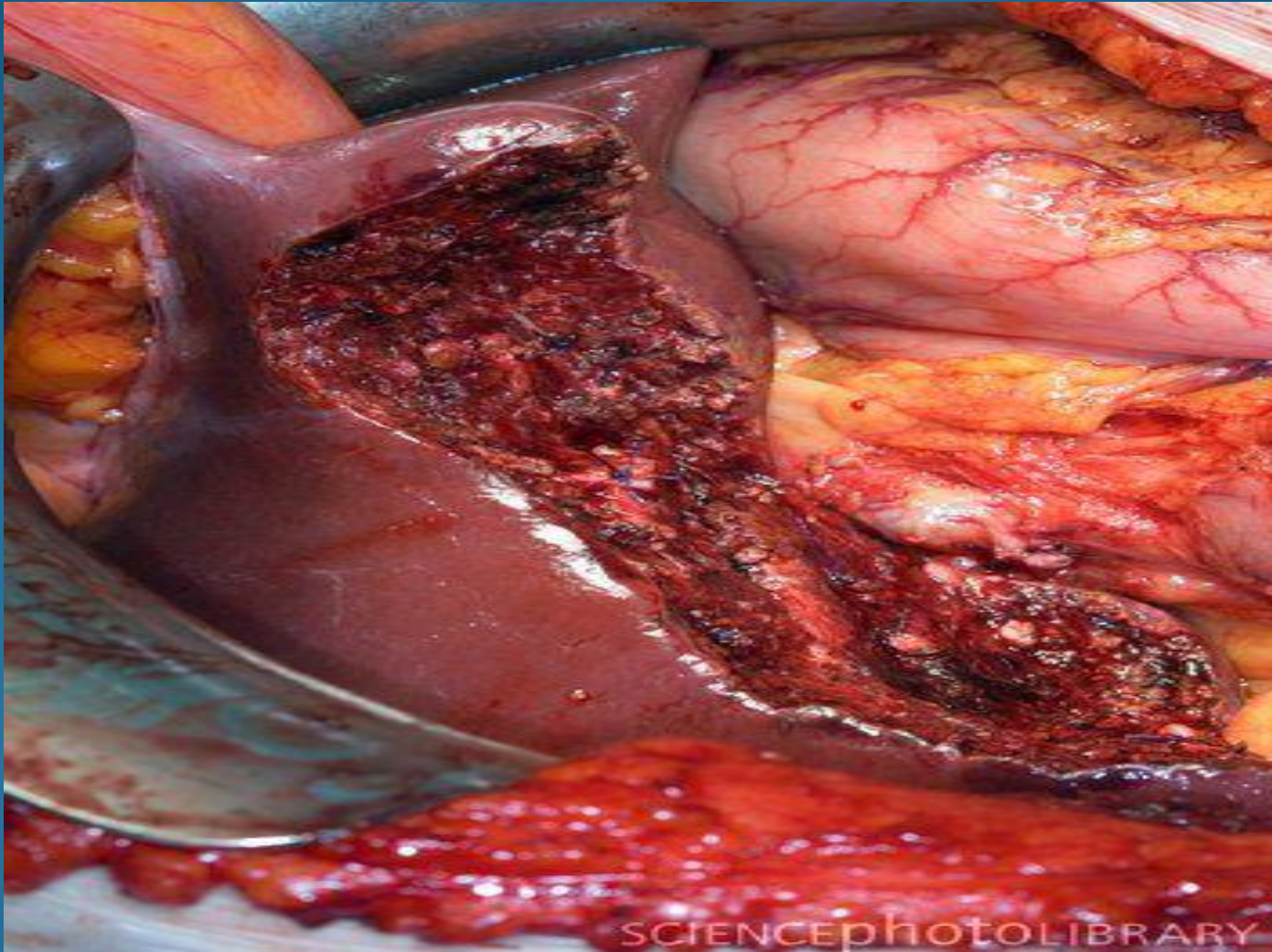
- 1- History of Primary Sclerosing Cholangitis (PSC)**
- 2- Congenital abnormalities**
- 3- Benign tumors of the bile ducts**
- 4- Hepatobiliary parasitic infection**
- 5- Toxic exposures thorium dioxid**

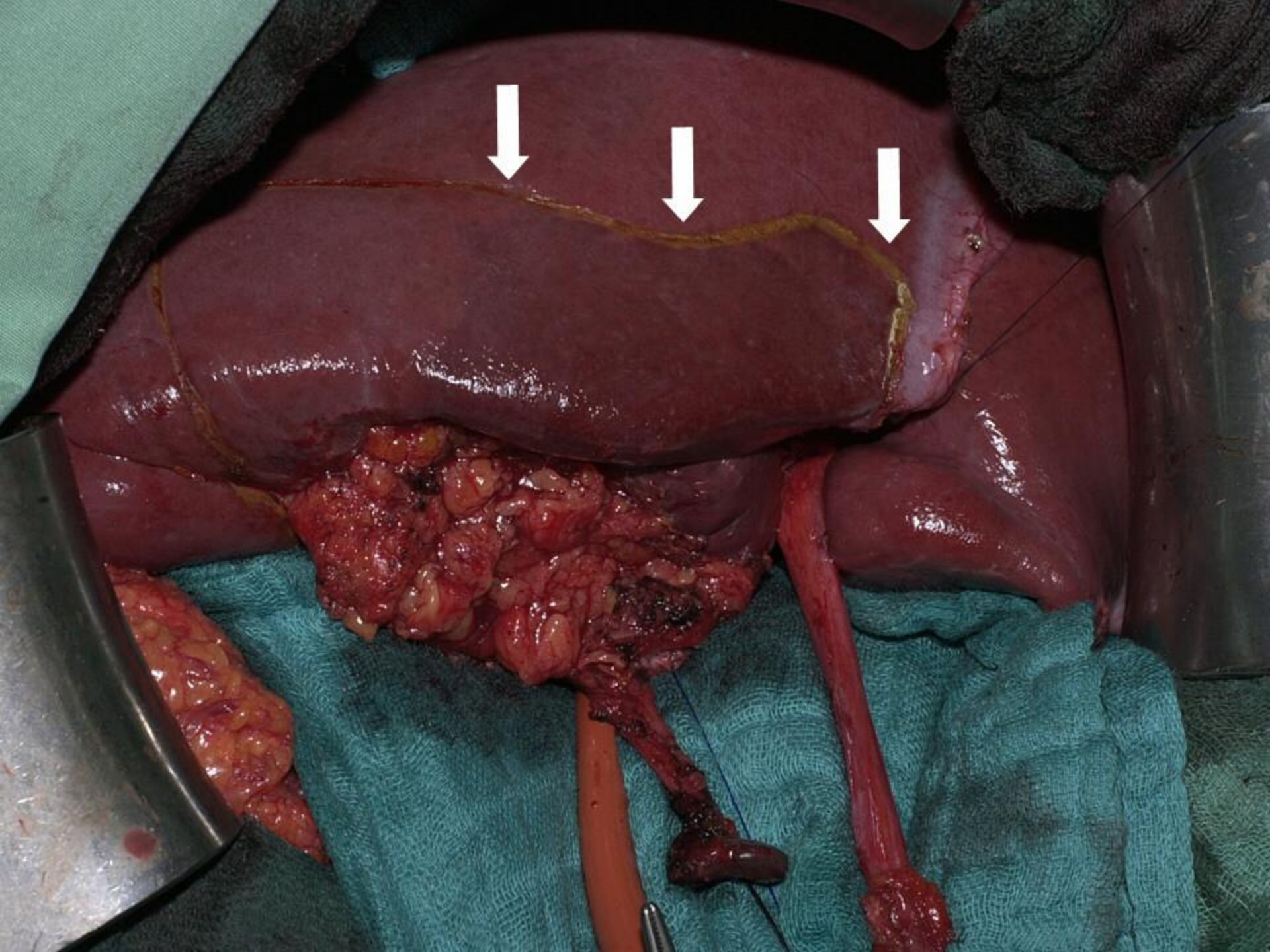
Treatment of Gallbladder and Bile Duct Cancer

complete removal of the liver (hepatectomy) with
liver

transplantationSurgical removal (resection)

Gallbladder cancer surgery





شكرا لإصغائكم

